J Renal Inj Prev. 2023; x(x): e32152.

https://journalrip.com doi: 10.34172/jrip.2023.32152

Journal of Renal Injury Prevention

An overview on the diagnostic role of electron microscopy for kidney diseases, study of 2006 native kidney biopsies in Iran

Seyed Mohammad Owji[1], Farshad Dehghani[2], Simin Torabinezhad[1], Seyed Hossein Owji[2,3], Hadi Raeisi Shahraki[4], Ashkan Karami[1*]

[1]Department of Pathology, Medical School, Shiraz University of Medical Sciences, Shiraz, Iran
[2]Student Research Committee, Shiraz University of Medical Sciences, Shiraz, Iran
[3]Otolaryngology Research Center, Department of Otolaryngology, Shiraz University of Medical Sciences, Shiraz, Iran
[4]Department of Biostatistics and Epidemiology, Faculty of Health, Shahrekord University of Medical Sciences, Shahrekord, Iran

ARTICLE INFO

Article Type:
Original

Article History:
Received: 20 October 2022
Accepted: 5 June 2023
Published online: 29 July 2023

Keywords:
Electron microscopy
Glomerulonephritis
Kidney
Kidney biopsy

ABSTRACT

Introduction: Kidney diseases affect millions of people worldwide. Over several decades, electron microscopy has been an integral part of the kidney biopsy study repertoire.
Objectives: In this study, we assessed the role of electron microscopy in the diagnosis of kidney diseases.
Patients and Methods: This was a retrospective cross-sectional study conducted at a referral center over a 16-year period (2001-2016). The electron microscopy (EM), light microscopy (LM), and immunofluorescence (IF) profiles of the patients were assessed. The final diagnosis was based on EM, and the primary LM results were compared to those of EM in order to assess the contribution rate of EM to the final diagnosis. The role of EM was categorized as essential, helpful, or non-contributory.
Results: A total of 2006 kidney biopsies were performed. Male subjects accounted for 44.3%, and adults for 74.1% of the cases. The most common diagnosis was lupus nephritis (LN) (20.7%), followed by focal segmental glomerulosclerosis (FSGS) (15.7%) and membranous glomerulonephritis (MGN) (14.5%). EM was the most contributory in hereditary nephritis and minimal change disease (MCD). Overall, EM was essential in 25.2%, helpful in 17.4%, and non-contributory in 57.4% of all 2006 cases.
Conclusion: The common kidney disorders in this geographic area of Iran are LN, FSGS, and MGN. In about half of the patients, EM study played an important role in the more accurate diagnosis of kidney diseases and prevented misdiagnosis. This role has been found to be more prominent in inherited diseases. We recommend EM as a useful and indispensable tool for routine pathologic study of biopsies when possible.

Original

Implication for health policy/practice/research/medical education:
The importance of electron microscopy in the pathological evaluation of kidney biopsies is paramount, particularly in cases involving pauci-immune glomerulopathies or ultrastructural involvement of the GBM. Often, the classification of kidney diseases necessitates a detailed electron microscopic evaluation. In instances where an electron microscope is unavailable, it is essential to set aside adequate tissue samples for further evaluation if the need arises.

Please cite this paper as: Owji SM, Dehghani F, Torabinezhad S, Owji SH, Raeisi Shahraki H, Karami A. An overview on the diagnostic role of electron microscopy for kidney diseases, study of 2006 native kidney biopsies in Iran. J Renal Inj Prev. 2023; x(x): e32152. doi: 10.34172/jrip.2023.32152.

Introduction

A kidney biopsy is an important tool for evaluating a patient with medical kidney diseases. There is substantial overlap in the clinical manifestations of various kidney diseases, and pathologic examination of tissues using light microscopy (LM), immunofluorescence microscopy (IFM), and electron microscopy (EM) assists nephropathologists in reaching the most accurate diagnosis possible.

Electron microscopy has been employed for diagnosing

***Corresponding author**: Ashkan Karami, Email: gpashkan@gmail.com, scrg21@gmail.com

nephropathies since the 1970s. EM provides a detailed evaluation of different aspects of the glomerular basement membrane (GBM), cellular matrix, and similar extracellular components, even surpassing light and fluorescent microscopic examinations in certain areas (1). In the 1990s, EM was an integral part of the diagnostic evaluation of kidney biopsies. This trend has changed thus far due to constant scientific advancements and newer diagnostic techniques, which has led to further focus on reevaluating the role of EM over the years.

Several advantages and some shortcomings were previously pointed out for EM (2). Regarding its merits, EM detects most forms of glomerular injury, such as deposition diseases (immune complex, others), epithelial cell damage, and defects of the GBM. Additionally, EM can be performed on small, unusual, or suboptimal tissue samples and provides increased resolution compared to other methods. Two notable shortcomings of EM are evident in focal/patchy glomerulonephritis (GN), which EM might miss, and non-specific GNs, like pauci-immune GN, which do not have a specific ultrastructural trademark.

EM has been reported to be essential in the diagnosis of hereditary nephritis (Alport syndrome, thin basement membrane disease (TBMD), Fabry disease), minimal change disease (MCD), nephronophthisis, focal segmental glomerulonephritis (FSGS), and dense deposit disease among the more important ones noted in certain studies (3).

The complex nature of glomerular diseases often necessitates a renal biopsy to establish a final diagnosis.

Various histological techniques have been employed to achieve the highest diagnostic value. LM and IF are routinely performed for all biopsies, while EM studies have been more selectively applied due to cost and time constraints.

Objectives

In this study, our objective was to provide an epidemiological overview of glomerular diseases across various age groups and genders, and ultimately evaluate the role of EM in reaching a definitive diagnosis for these diseases. The current research is particularly noteworthy due to its novel, large-scale referral center assessment of EM in Iran.

Patients and Methods

Study design

This was a retrospective cross-sectional study conducted at hospitals affiliated with Shiraz University of Medical Sciences (Shiraz, Iran). The study focused on patient renal biopsies with EM diagnoses made between 2001 and 2016. Data were extracted from the following sources: pathology reports, EM study reports and request sheets, pathology and toluidine blue slides, and EM grids. All renal biopsies from the 16-year period were processed at the same institution.

Inclusion criteria

The study included all patients who underwent a renal biopsy (native kidney) with adequate tissue for EM and ultrastructural evaluation between 2001 and 2016.

Exclusion criteria

Patients who had specimens with technical failure in LM/EM (inadequate tissue for evaluation), and specimens on which LM/EM study was not conducted.

Microscopic study

Renal biopsies were divided into LM, IF, and EM:

Electron microscopy

The samples were placed in a cold solution of 3% glutaraldehyde in cacodylate buffer, and the most convenient and routine fixation method was glutaraldehyde fixation with post-osmification. Subsequently, for tissue embedding, epoxy resins were used. Semi-thin (1 µm thick) sections obtained from the plastic-embedded tissue blocks were stained with toluidine blue and carefully studied by LM, as they can yield a great deal of information, particularly when examined at high magnification. Ultra-thin sections with 90-nm thickness from the blocks were selected for ultrastructural study and double-stained with uranyl acetate and lead citrate for electron microscopic examination. Afterwards, the grids were analyzed under the transmission electron microscope (Leo 906, Germany).

Immunofluorescence

The samples were snap-frozen in liquid nitrogen or in isopentane cooled on dry ice. Frozen sections, 2-4 µm thick, were cut and stained with specific antibodies (IgG, IgM, IgA, C3, and C1q) and examined under ultraviolet light using either transmitted or incident illumination. The reactions were graded subjectively based on a scale of 0 to 3+.

Light microscopy

The samples were transferred to a fixative, the most common being 10% buffered formalin. Special stains included periodic acid-Schiff , Masson trichrome, and methenamine silver.

Determining the role of electron microscopy in the diagnosis of kidney diseases

For all the biopsies in which both light and EM were performed, primary LM findings were compared to those of EM final diagnosis. The agreement of light and EM is described in the categories of data represented in Table 1.

- Category 1: one (or more) of several LM diagnoses agreed with EM diagnoses.
- Category 2: one (or more) of several LM diagnoses agreed with EM diagnoses, and EM added another

Table 1. Agreement between light microscopy and electron microscopy in the case diagnoses of patients who underwent kidney biopsy

EM diagnosis	Total number (%)	Essential	Helpful	Noncontributory
MesPGN	282 (12.7)	54 (29.8)	48 (17.0)	150 (53.2)
PSGN	13 (0.6)	3 (23.1)	0 (0)	10 (76.9)
CresGN	45 (2.0)	0 (0)	18 (40.0)	27 (60.0)
MGN	313 (14.1)	53 (16.9)	26 (8.3)	234 (74.8)
MCD	121 (5.4)	56 (46.3)	65 (53.7)	0 (0)
FSGS	339 (15.2)	110 (32.4)	72 (21.2)	157 (46.3)
Global GS	258 (11.6)	70 (27.1)	101 (39.1)	87 (33.7)
MPGN	109 (4.9)	28 (25.7)	16 (14.7)	65 (59.6)
IgAN	7 (0.3)	3 (42.9)	4 (57.1)	0 (0)
Necrotizing GN	10 (0.4)	2 (20.0)	5 (50.0)	3 (30.0)
LN	447 (20.1)	2 (0.5)	10 (2.2)	435 (97.3)
Diabetic nephropathy	28 (1.3)	5 (17.9)	7 (25.0)	16 (57.1)
Amyloidosis	26 (1.2)	4 (15.4)	1 (3.8)	21 (80.8)
HUS	12 (0.5)	3 (25.0)	1 (8.3)	8 (66.7)
Vasculitis	1 (0.0)	0 (0)	0 (0)	1 (100)
Alport	11 (0.5)	9 (81.8)	2 (18.2)	0 (0)
TBMD	4 (0.2)	3 (75.0)	1 (25.0)	0 (0)
Fabry	2 (0.1)	2 (100)	0 (0)	0 (0)
Congenital NS	3 (0.1)	1 (33.3)	1 (33.3)	1 (33.3)
Normal	125	105 (84.0)	1 (0.8)	19 (15.2)
Total	2156	543 (25.2)	376 (17.4)	1237 (57.4)

GN; Glomerulonephritis, GS; Glomerulosclerosis, MesPGN; Mesangioproliferative GN, PSGN; Post Streptococcal GN, CresGN; Crescentic GN, MGN; Membranous GN, MCD; Minimal change disease, FSGS; Focal Segmental GS, MPGN; Membranoproliferative GN, IgAN; IgA nephropathy, HUS; Hemolytic uremic syndrome, TBMD; Thin basement membrane disease, Congenital NS; Congenital nephrotic syndrome.

diagnosis.

- Category 3: EM diagnoses agreed with all the LM diagnoses and added another diagnosis.
- Category 4: All the LM diagnoses were exactly the same as EM diagnoses.
- Category 5: LM and EM diagnoses were completely different.

Categories 1-3 were designated as helpful, category 4 as non-contributory, and category 5 as essential.

Statistical analysis

SPSS version 23 was conducted for analysis purposes. For inter-variable correlation analysis, Pearson's correlation coefficient, *t* test, and chi-square test were applied, and at the descriptive level, percentage, mean, and standard deviation were utilized. A P value < 0.05 was considered statistically significant.

Results

General structure of data

The total number of patients in this study was 2,006. Male subjects comprised 44.3% of the cases, with a 74.1/25.9% adult-to-children (age < 18 years) ratio. The mean age of the patients was 10.5 ± 5.5 years for children, 37.0 ± 13.8 years for adults, and 29.9 ± 16.8 years for all patients in total. The most common diagnoses overall included lupus nephritis (LN) (20.7%), FSGS (15.7%), and membranous glomerulonephritis (MGN) (14.5%). The most common diagnosis in adults was LN, while in children, it was mesangioproliferative glomerulonephritis (MesPGN). The mean number of glomeruli for LM was 14.9 ± 8.7, and for EM, it was 6.5 ± 4.2 (Table 2). Table 2 depicts the demographic data and disease categorizations. Table 1 demonstrates the agreement between light and EM. Some patients had multiple diagnoses; therefore, the total number of diagnoses (2156) in the tables outnumbered the patients (2006).

The association of gender and age with different diseases

MesPGN, crescentic GN (CresGN), MGN, FSGS, global glomerulosclerosis (GS), membranoproliferative GN (MPGN), IgA nephropathy (IgAN), LN, diabetic nephropathy, and Fabry disease were significantly more prevalent in adult patients. Amyloidosis was only detected among the adult population. In contrast, hemolytic uremic syndrome (HUS) was more prevalent in children (P<0.05), and thin basement membrane nephropathy and congenital nephrotic syndrome (NS) were only detected in children. Regarding gender, LN was more prevalent among females and global GS among males.

Table 2. Demographic and epidemiologic data of the case diagnoses of patients who underwent kidney biopsy

EM diagnosis	Total number (%)	Gender			Age (mean± SD)	Age group		
		Male	Female	*P* value		Children	Adult (>18)	*P* value
MesPGN	282 (13.1)	140(49.6)	142(50.4)	0.95	25.3± 15.9	108 (38.3)	174 (61.7)	<0.001
PSGN	13 (0.6)	6 (46.2)	7 (53.8)	0.99	24.5± 16.9	6 (46.2)	7 (53.8)	0.99
CresGN	45 (2.1)	19 (42.2)	26 (57.8)	0.37	31.6±19.5	13 (28.9)	32 (71.1)	0.01
MGN	313 (14.5)	172 (55.0)	141 (45.0)	0.09	37.6±15.7	33 (10.5)	280 (89.5)	<0.001
MCD	121 (5.6)	68 (56.2)	53 (43.8)	0.20	22.7±16.7	52 (43.0)	69 (57.0)	0.15
FSGS	339 (15.7)	179 (52.8)	160 (47.2)	0.33	29.5±17.2	94 (27.7)	245 (72.3)	<0.001
Global GS	258 (12.0)	153 (59.3)	105 (40.7)	0.003	32.4±18.1	51 (19.8)	207 (80.2)	<0.001
MPGN	109 (5.1)	54 (49.5)	55 (50.5)	0.99	29.7±17.9	30 (27.5)	79 (72.5)	<0.001
IgAN	7 (0.3)	3 (42.9)	4 (57.1)	0.99	23.9±6.5	2 (7.1)	26 (92.9)	<0.001
Necrotizing GN	10 (0.4)	4 (40.0)	6 (60.0)	0.75	40.2± 19.8	2 (20.0)	8 (80.0)	0.11
LN	447 (20.7)	65 (14.5)	382 (85.5)	<0.001	28.2±11.9	96 (21.5)	351 (78.5)	<0.001
Diabetic nephropathy	28 (1.3)	12 (42.9)	16 (57.1)	0.57	42.6±15.6	2 (7.1)	26 (92.9)	<0.001
Amyloidosis	26 (1.2)	16 (61.5)	10 (38.5)	0.33	55.4±12.8	0 (0)	26 (100)	<0.001
HUS	12 (0.5)	5 (41.7)	7 (58.3)	0.77	9.6±7.9	11 (91.7)	1 (8.3)	0.01
Vasculitis	1 (0.0)	1 (100)	0 (0)	0.99	39.0±0.0	0 (0)	1 (100)	0.55
Alport	11 (0.5)	5 (45.5)	6 (54.5)	0.99	16.0±7.1	7 (63.6)	4 (36.4)	0.55
TBMD	4 (0.2)	2 (50.0)	2 (50.0)	0.99	8.2±1.7	4 (100)	0 (0)	0.12
Fabry	2 (0.1)	2 (100)	0 (0)	0.50	36.0±0.0	0 (0)	2 (100)	0.50
Congenital NS	3 (0.1)	2 (66.7)	1 (33.3)	0.99	3.4±3.0	3 (100)	0 (0)	0.25
Normal	125 (5.8)	48 (38.4)	77 (61.6)	0.01	26.3±17.2	44 (35.2)	81 (64.8)	0.001
Total	2156	956 (44.3)	1200 (55.7)	<0.001	29.9±16.8	558 (25.9)	1598 (74.1)	<0.001

GN; Glomerulonephritis, GS; Glomerulosclerosis, MesPGN; Mesangioproliferative GN, PSGN; Post streptococcal GN, CresGN; Crescentic GN, MGN; Membranous GN, MCD; Minimal Change Disease, FSGS; Focal segmental GS, MPGN; Membranoproliferative GN, IgAN; IgA nephropathy, HUS; Hemolytic uremic syndrome, TBMD; Thin basement membrane disease, Congenital NS; Congenital nephrotic syndrome.

Children showed a higher prevalence of hereditary glomerular diseases (Alport syndrome, TBMD, Fabry disease and congenital NS), however this difference was not statistically significant, and there was no meaningful difference between the genders (Table 2). Overall, there were more adults in our study ($P < 0.001$).

Role of electron microscopy in the diagnosis of kidney diseases

The roles of EM in diagnosing selected kidney diseases are depicted in Figure 1, while electron photomicrographs of various kidney diseases are illustrated in Figures 2 to 4. The usefulness of EM in each case can be categorized as essential, helpful, or non-contributory.

In all the cases of IgAN, MCD, Alport syndrome, TBMD and Fabry disease, EM was helpful or essential (Table 1). Similarly, EM significantly contributed to the diagnosis (helpful/essential in more than 50% of cases) in necrotizing GN (70.0%), congenital NS (66.7%), global GS (66.3%), and FSGS (53.7%) (Table 1).

In total, EM was essential in 25.2%, helpful in 17.4%, and non-contributory in 57.4% of the 2,156 diagnoses (Table 1).

Immunofluorescence study

The IF study was carried out for 81.9% of the cases. The most common overall IF pattern was IgG (38.3%), closely followed by C3 (32.2%). The IF study was negative in 672 cases (38.1%). It was positive in all cases of post-streptococcal glomerulonephritis (PSGN) and IgAN. The IF study with positive IgG was most frequently observed in MGN, MPGN, and LN. IgAN was observed in 45 cases out of 220, for whom IF was done among mesangioproliferative GN cases. IF was mostly negative in patients with hereditary nephritis.

Discussion

We retrospectively retrieved biopsy reports and pathology request forms for each case and recorded the final diagnosis based on EM in conjunction with LM and IF results. We made an effort to categorize the agreement between EM and LM/IFM into several categories and ultimately

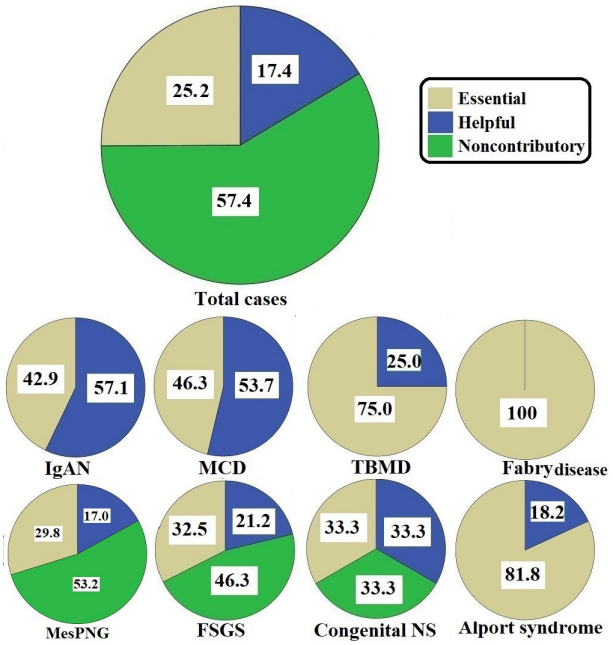

Figure 1. Contribution of electron microscopy to renal biopsy specimens in various kidney disorders (percentage).

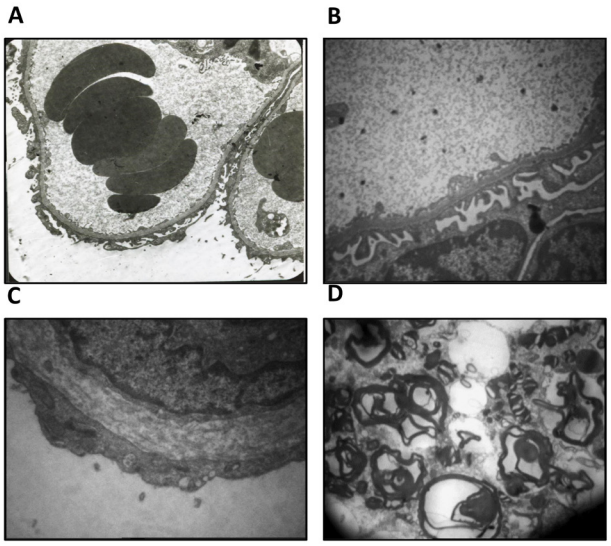

Figure 2. (A) Electron microscopy micrograph of normal glomerulus with normal thickness of the capillary basement membrane (about 330 nm). (**B**) Thin basement membrane disease showing uniform thinning of the capillary basement membrane (about 200 nm). The foot processes of podocytes are normal. (**C)**Alport Syndrome showing diffuse irregular thinning and widening and splitting of lamina densa of the basement membrane of the capillary wall and basket-weave lamellation. (**D)** In Fabry Disease, there is a massive accumulation of laminated round inclusion bodies with onion skin appearance in the cytoplasm of the visceral epithelial cells and mesangial cells of the glomerulus with a few Zebra body formations. (Uranyl acetate and lead citrate; **A** and **B** ×3597, **C**×6000, and **D**×2784.)

arranged them into three groups, based on the usefulness and necessity of EM for reaching the final diagnosis. An overview of our findings, relative to previous publications, can be found in Table 3.

FSGS has consistently been the most common diagnosis in numerous studies; however, there have been a few exceptions. For example, a Chinese systematic review study of more than 176 000 cases by Yang et al (16) found that IgAN (24.3%) was the most common diagnosis, while only 4.6% of their cases were FSGS. Another study by Bakr et al (17) on 1096 pediatric kidney biopsies in Egypt revealed MCD (21.8%) and diffuse proliferative GN (15.3%) as the most frequent diagnoses. Moreover, there were a few cases of IgAN in our work, which, considering the fact that other studies across the world have reported differing IgAN frequencies, might be explainable by ethno-geographic distribution of IgAN or simply differing nephrology practices (16,18-23).

In this research, we found that the majority of kidney diseases were more prevalent in adults, and except for LN, which was much more common in females, no significant gender differences were observed overall. Therefore, with LN being the most common diagnosis, there were more females in our study. Additionally, HUS was more prevalent in children; hereditary GN was only detected in children, and amyloidosis was only detected in adults. Our results are generally consistent with previous investigations. There were a number of differences between genders concerning the prevalence of kidney diseases. In the same vein, Polito et al reported a higher percentage of males in GNs, except for proliferative type GNs, and female predominance in LN cases (19). In the research by

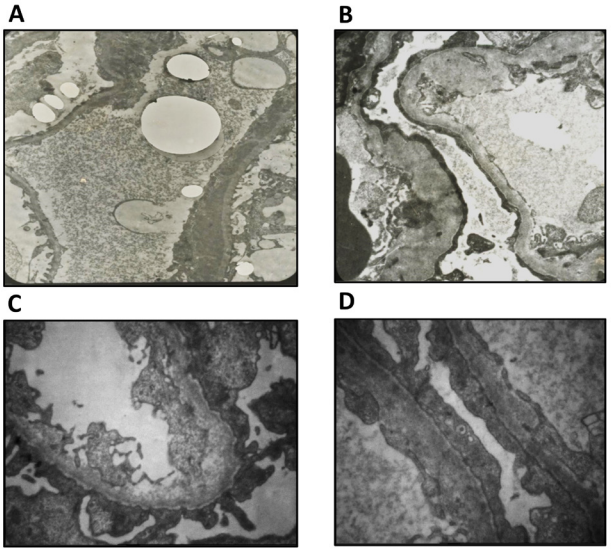

Figure 3. (A). A capillary loop in diffuse lupus nephritis, showing a large amount of electron-dense immune complex deposits in the subendothelial area and in the mesangial area, like a mountain range. **(B and D)**. The capillary wall of the glomerulus in minimal change disease demonstrates complete flattening and effacement of the foot processes of the podocytes with microcyst formation in the cytoplasm of the epithelial cells. **(C)**. The capillary wall of the glomerulus in hemolytic uremic syndrome showing prominent diffuse electron lucent zone in the subendothelial area of the basement membrane (Uranyl acetate and lead citrate. **A** ×3597, **B**×7750, **C**×7750, **D**×10000).

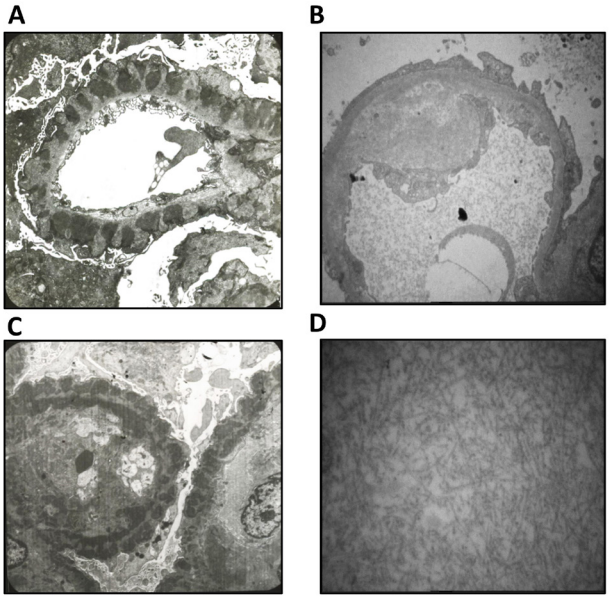

Figure 4. (**A**) MGN stage 3 revealing multiple electron dense depositions in the subepithelial area of basement membrane. (**B**) Electron micrograph showing homogenous electron-pale deposits in the intramembranous and subendothelial area in renal amyloidosis. (**C**) A portion of glomerulus capillary loop in MPGN type III showing numerous subepithelial and subendothelial deposits. (**D**) Non-branching straight amyloid fibrils with a diameter of 8-12 nm are randomly oriented, in renal amyloidosis (Uranyl acetate and lead citrate. **A**×3597, **B**×3597, **C**×2784, **D**×27800).

Dos-Santos et al, the prevalence of LN in females reached 36% (21). This point was also noted in other studies. In one study, MCD and FSGS were more prevalent in males, while LN was mostly observed in females (23). Hereditary nephritis has historically been reported more frequently in studies of the pediatric population (15,24).

In our study, EM was essential for renal diagnosis in 25.2% of cases and helpful in 17.4% of cases. EM did not contribute to the diagnosis in 57.4% of cases. Therefore, EM was found to be essential for or conducive to diagnosis in 41.5% of cases where comparison was possible. The areas where EM contributed most to diagnosis included hereditary nephritis, MCD, and surprisingly, IgAN. EM contributed to diagnosis in all of the hereditary, MCD, and IgAN cases (n = 7). We had a very low frequency of IgAN; thus, selection bias might skew the actual use of EM in this disease, as some studies have pointed out that EM was of little to no help in IgAN (8,16). In studies by Zhang et al and Sementilli et al, EM was also most helpful where IF microscopy was negative (6,15). Meanwhile, there were studies in which EM contributed to IgAN diagnosis to some degree; for instance, Darouich et al studied 20 biopsies, in which four IgAN cases needed EM for the final diagnosis, either for confirmation or otherwise (10). Similarly, an Egyptian investigation by Elhefnawy found that EM contributed to the final diagnosis in 70% of IgAN cases (11). EM also contributed to diagnosis in all the MCD cases. This has been consistently mentioned in numerous other papers as well (9,13,14). MCD fundamentally affects epithelial foot processes, which can only be examined under EM.

One of the most negligible contributions of EM to diagnosis was observed among LN cases (2.7%). Nonetheless, the importance of EM study in LN cannot be ignored since it is necessary for the correct classification of LN types, specifically in mixed cases of LN. In one study, Wagrowska-Danilewicz and Danilewicz concluded that EM was contributory to precise subtyping and classification of glomerular diseases; for instance, EM was essential for accurate diagnosis in over 20% of LN cases (8). EM contributed to diagnosis in 42.9% of diabetic nephropathies, which was higher compared to that in other studies. EM was helpful for diagnosing diabetic

Table 3. List of publications that focused on the role of electron microscopy in renal diseases

Author	Year/Country	Number of cases	Essential (%)	Helpful (%)	Non-contributory (%)
Pearson et al (4)	1994/UK	88	25	50	25
Haas (5)	1997/US	233	21	21	58
Sementilli et al (6)	2004/Brazil	200	10	5.5	77
Collan et al (7)	2005/Finland	85	18.3	53.5	28.2
Wagrowska-Danilewicz and Danilewicz (8)	2007/Poland	113	31	13.3	55.7
Mubarak and Kazi (9)	2009/Pakistan	200	43	51.5	5.5
Darouich et al (10)	2010/Tunisia	20 (52)	40	60	-
Elhefnawy (11)	2011/Egypt	120	25	41.7	33.3
Zuppan (12)	2011/USA	80 (pediatric)	63	23	11
Kurien et al (13)	2016/India	115	12	20	68
Arslansoyu et al (3)	2019/Turkey	48 (pediatric)	31	65	4
L'Imperio et al (14)	2020/Italy	340	22	48	30
Zhang et al (15)	2020/China	855 (pediatric)	35.1	32.7	32.2
Our study	2022/Iran	2156	25.2	17.4	57.4

nephropathy as an additional diagnosis by showing GBM thickness in one study (5), whereas in another recent paper, EM had little contribution to the diagnosis of diabetic nephropathy cases (14).

Hereditary nephritis comprised 11 cases of Alport syndrome, four cases of thin basement membrane nephropathy, three cases of congenital nephrotic syndrome, and two cases of Fabry disease. EM contributed to the diagnosis of 100% of the Alport syndrome, thin basement membrane nephropathy, and Fabry disease cases, and 66.7% of the congenital nephrotic syndrome cases. Hereditary nephritis has consistently demonstrated the highest need for EM, which is typically essential for diagnosis in several studies (8,14,15,20). Since hereditary nephritis is IF-negative and LM appears normal, EM is the only definitive diagnostic method for this category. Furthermore, because hereditary GN is usually present from birth, patients become symptomatic in childhood, making the contribution of EM in childhood kidney biopsies higher than in adults (15).

There were 1,765 (81.9%) cases for which IFM was performed. Among them, 1,093 (61.9%) were IF-positive, while IgG and C3 were each positive in 579 and 493 cases, respectively. IF was positive in all the cases of PSGN and IgAN. IF is essential for detecting immunoglobulin and complement deposits by type and location, enabling the correct diagnosis and classification of most cases of LN, IgAN, MPGN, and MGN (6,10). For IF-negative cases, most studies agree that EM is more helpful (15). However, this is not always the case when IFM/LM diagnosis is not confirmed with EM, and several studies have reported cases in which EM entirely changed the diagnosis (3,14).

In summary, EM has been in use since the late 20th century, and its functionality has not declined over the decades, if not increased (Table 3). This point was also emphasized by Haas et al, who treated ultrastructural study as an equal entity to LM in the latest major revision of pathological characteristics and definitions for different glomerular lesions (25). Ultimately, EM has the advantage of providing semi-thin toluidine blue survey sections, which offer higher accuracy than routine LM slides. In cases where the tissue is not preserved for EM, sections of paraffin-embedded or frozen-section samples can be retrieved and used for ultrastructural study. Despite lower quality, these samples would still be diagnostic in the majority of cases. Therefore, several publications have repeatedly recommended EM as a routine study, given that its necessity cannot be assessed unless performed.

Conclusion

The most prevalent kidney disorders in this geographic region of Iran are LN, FSGS, and MGN. In approximately half of the patients, EM study played a crucial role in ensuring a more accurate diagnosis of kidney diseases, preventing misdiagnosis. This role was especially significant in cases of Fabry's disease, Alport syndrome, TBMD, and MCD. We recommend EM as a valuable and indispensable tool for routine pathological study of biopsies, whenever possible.

Limitations of the Study

There were certain limitations to our study that need to be considered. First, the pathology request forms completed by the clinicians were, in some instances, incomplete or illegible due to wear and tear. Second, our research was conducted retrospectively; thus, patient follow-up for repeated biopsies or disease outcomes was not entirely feasible for this number of cases.

Acknowledgments

The authors would like to thank Ms. Hamideh Jabedarbashy (technician of the EM unit). The present article was extracted from the thesis written by Ashkan Karami.

Authors' contribution

Conceptualization: SMO, AK.
Methodology: SMO, HRS, SHO.
Validation: SMO.
Formal analysis: HRS.
Investigation: FD, SHO, AK, ST, SMO.
Resources: FD, SHO, AK, HRS.
Data curation: FD, SHO, AK, HRS.
Writing–original draft preparation: FD.
Writing–review and editing: SMO, SHO, ST.
Visualization: SMO.
Supervision: SMO.
Project administration: SMO.
Funding acquisition: SMO.

Conflicts of interest

The authors have no conflicts of interest to declare.

Ethical issues

The research adhered to the principles outlined in the Declaration of Helsinki. The Ethics Committee of Shiraz University of Medical Sciences approved this study (Ethical code#IR.SUMS.MED.REC.1399.380). In accordance with these guidelines, written informed consent was obtained from all participants prior to any intervention. Ethical issues (including plagiarism, data fabrication, double publication) have been completely observed by the authors.

Funding/Support

The study received financial support from Shiraz University of Medical Sciences, Shiraz, Iran (Grant #20505).

References

1. Goldblum JR. Rosai and Ackerman's Surgical Pathology. 11th ed. Philadelphia, PA: Elsevier. 2018

2. Pavlisko EN, Howell DN. The continued vital role of electron microscopy in the diagnosis of renal disease/dysfunction. Ultrastruct Pathol. 2013;37:1-8. doi: 10.3109/01913123.2012.670025
3. Arslansoyu Camlar S, Ünlü M, Soylu A, Karaca D, Sarioglu S, Kavukcu S. Contribution of electron microscopy to the clinicopathologic diagnosis in childhood glomerular renal diseases. Fetal Pediatr Pathol. 2019;38:299-306. doi: 10.1080/15513815.2019.1587119
4. Pearson JM, McWilliam LJ, Coyne JD, Curry A. Value of electron microscopy in diagnosis of renal disease. J Clin Pathol. 1994;47:126-8. doi: 10.1136/jcp.47.2.126
5. Haas M. A reevaluation of routine electron microscopy in the examination of native renal biopsies. J Am Soc Nephrol. 1997;8:70-6. doi: 10.1681/ASN.V8170
6. Sementilli A, Moura LA, Franco MF. The role of electron microscopy for the diagnosis of glomerulopathies. Sao Paulo Med J. 2004;122:104-9. doi: 10.1590/s1516-31802004000300006
7. Collan Y, Hirsimäki P, Aho H, Wuorela M, Sundström J, Tertti R, et al. Value of electron microscopy in kidney biopsy diagnosis. Ultrastruct Pathol. 2005;29:461-8. doi: 10.1080/01913120500323381
8. Wagrowska-Danilewicz M, Danilewicz M. Current position of electron microscopy in the diagnosis of glomerular diseases. Pol J Pathol. 2007;58:87-92.
9. Mubarak M, Kazi JI. Role of immunofluorescence and electron microscopy in the evaluation of renal biopsies in nephrotic syndrome in a developing country. Ultrastruct Pathol. 2009;33:260-4. doi: 10.3109/01913120903296952
10. Darouich S, Goucha RL, Jaafoura MH, Moussa FB, Zekri S, Maiz HB. Value of electron microscopy in the diagnosis of glomerular diseases. Ultrastruct Pathol. 2010;34:49-61. doi: 10.3109/01913120903506637
11. Elhefnawy NG. Contribution of electron microscopy to the final diagnosis of renal biopsies in Egyptian patients. Pathol Oncol Res. 2011;17:121-5. doi: 10.1007/s12253-010-9290-6
12. Zuppan C. Role of electron microscopy in the diagnosis of nonneoplastic renal disease in children. Ultrastruct Pathol. 2011;35:240-4. doi: 10.3109/01913123.2011.606394
13. Kurien AA, Larsen C, Rajapurkar M, Bonsib SM, Walker P. Lack of electron microscopy hinders correct renal biopsy diagnosis: A study from India. Ultrastruct Pathol. 2016;40:14-7. doi: 10.3109/01913123.2015.1120837
14. L'Imperio V, Brambilla V, Cazzaniga G, Ferrario F, Nebuloni M, Pagni F. Digital pathology for the routine diagnosis of renal diseases: a standard model. J Nephrol. 2021;34:681-688. doi: 10.1007/s40620-020-00805-1
15. Zhang X, Xu J, Xiao H, Yao Y, Wang H, Ren Y, et al. Value of electron microscopy in the pathological diagnosis of native kidney biopsies in children. Pediatr Nephrol. 2020;35:2285-2295. doi: 10.1007/s00467-020-04681-6
16. Yang Y, Zhang Z, Zhuo L, Chen DP, Li WG. The Spectrum of Biopsy-Proven Glomerular Disease in China: A Systematic Review. Chin Med J (Engl). 2018;131:731-735. doi: 10.4103/0366-6999.226906
17. Bakr A, Eid R, Sarhan A, Hammad A, El-Refaey AM, El-Mougy A, et al. Fifteen years of kidney biopsies in children: a single center in Egypt. Saudi J Kidney Dis Transpl. 2014;25:1321-7. doi: 10.4103/1319-2442.144307
18. Honma M, Toyoda M, Umezono T, Kato M, Kobayashi K, Miyauchi M, et al. An investigation of 2,093 renal biopsies performed at Tokai University Hospital between 1976 and 2000. Clin Nephrol. 2008;69:18-23. doi: 10.5414/cnp69018.
19. Polito MG, de Moura LA, Kirsztajn GM. An overview on frequency of renal biopsy diagnosis in Brazil: clinical and pathological patterns based on 9,617 native kidney biopsies. Nephrol Dial Transplant. 2010;25:490-6. doi: 10.1093/ndt/gfp355
20. Perkowska-Ptasinska A, Bartczak A, Wagrowska-Danilewicz M, Halon A, Okon K, Wozniak A, et al. Clinicopathologic correlations of renal pathology in the adult population of Poland. Nephrol Dial Transplant. 2017;32:ii209-ii218. doi: 10.1093/ndt/gfw365
21. Dos-Santos WLC, Sweet GMM, Azevêdo LG, Tavares MB, Soares MFS, Melo CVB, et al. Current distribution pattern of biopsy-proven glomerular disease in Salvador, Brazil, 40 years after an initial assessment. J Bras Nefrol. 2017;39:376-383. English, Portuguese. doi: 10.5935/0101-2800.20170069
22. Al Arrayed A, Shariff S, Al Maamari MM. Kidney disease in Bahrain: a biopsy based epidemiologic study. Saudi J Kidney Dis Transpl. 2007;18:638-42.
23. Muthu V, Ramachandran R, Nada R, Kumar V, Rathi M, Kohli HS, et al. Clinicopathological spectrum of glomerular diseases in adolescents: a single-center experience over 4 years. Indian J Nephrol. 2018;28:15-20. doi: 10.4103/ijn.IJN_239_16
24. Arapović A, Vukojević K, Filipović N, Glavina Durdov M, Ljubanović-Galešić D, Saraga-Babić M, et al. Epidemiology of 10-year paediatric renal biopsies in the region of southern Croatia. BMC Nephrol. 2020;21:65. doi: 10.1186/s12882-020-01727-7
25. Haas M, Seshan SV, Barisoni L, Amann K, Bajema IM, Becker JU, et al. Consensus definitions for glomerular lesions by light and electron microscopy: recommendations from a working group of the Renal Pathology Society. Kidney Int. 2020;98:1120-1134. doi: 10.1016/j.kint.2020.08.006.

Copyright © 2023 The Author(s); Published by Nickan Research Institute. This is an open-access article distributed under the terms of the Creative Commons Attribution License (http://creativecommons.org/licenses/by/4.0), which permits unrestricted use, distribution, and reproduction in any medium, provided the original work is properly cited.