

Colovesical fistula in a 11-year-old girl with ambiguous genitalia and recurrent urinary tract infection; a brief report

Paniz Pourpashang¹ , Seyed Mohammad Taghi Hosseini Tabatabaei¹ , Arefeh Zahmatkesh^{2*} , Mina Vatanpour³ 

¹Department of Pediatric Nephrology Research Center, Research Institute for Children's Health, Shahid Beheshti University of Medical Sciences, Tehran, Iran

²School of Medicine, Shahid Beheshti University of Medical Sciences, Tehran, Iran

³Department of Pediatric Nephrology, Shahid Beheshti Medical University, Tehran, Iran

ARTICLE INFO

Article Type:
Case Report

Article History:

Received: 21 June 2023

Accepted: 15 August 2023

Published online: 31 August 2023

ABSTRACT

VACTERL (V-Vertebral, A-Anorectal, C-Cardiac, TE-Tracheoesophageal, R-Renal, L-Limb) is an acronym for multiple organ dysfunction, which often occurs together. These prospects may affect patients with other abnormalities, such as urogenital abnormalities. Here we present a case of VACTERL syndrome with ambiguous genitalia who was referred and hospitalized due to recurrent urinary tract infection (UTI) and urosepsis. A colovesical fistula was discovered in the following examinations, which could explain this complication.

Keywords: VACTERL association, fistula, recurrent urinary tract infection, ambiguous genitalia

Implication for health policy/practice/research/medical education:

It is essential to be aware of the co-existing comorbidities associated with VACTERL (V-Vertebral, A-Anorectal, C-Cardiac, TE-Tracheoesophageal, R-Renal, L-Limb) syndrome, as these may have a crucial impact on prognosis and outcome.

Please cite this paper as: Pourpashang P, Hosseini Tabatabaei SMT, Zahmatkesh A, Mina Vatanpour M. Colovesical fistula in a 11-year-old girl with ambiguous genitalia and recurrent urinary tract infection; a brief report. J Renal Inj Prev. 2023; 12(4): e32206. doi: 10.34172/jrip.2023.32206.

Introduction

Ambiguous genitalia is a birth anomaly that embodies an unrecognizable gender due to the atypical appearance of the external genitalia. A disruption in the sex chromosome caused by environmental and genetic components results in ambiguous genitalia (1). Sex chromosome differences of sex development as; ovotesticular, common in karyotype 46xx in VACTERL (V-Vertebral, A-Anorectal, C-Cardiac, TE-Tracheoesophageal, R-Renal, L-Limb) patients (2).

VACTERL is a rare congenital multi-organ malfunction with an incidence rate 1/10,000-1/40,000 in the newborn (3). The diagnosis of VACTERL is in the presence of three or more of these involvements (4). abnormalities of the renal and urinary were commonly reported in 60- 90% of VACTERL patients, and several studies showed that they were diagnosed in patients with VACTERL syndrome (5). A study conducted by Solomon. et al. showed that recto-vestibular or recto-urethral fistula, often associated with anorectal malformations, could be related to VACTERL

syndrome (6). In addition, statistical data provided evidence of urogenital abnormalities, which are common in VAVTERL patients with renal abnormalities and anorectal atresia (7,8).

Due to the complicity of the seven core characteristics of VACTERL syndrome, as well as the other anomalies that accompany them (e.g., genitourinary anomalies), identifying all abnormalities and initiating clinical treatment could optimize medical care. Here we presented a brief report of a known VACTERL syndrome involving genitourinary system anomalies with recurrent urinary tract infection (UTI), who was finally diagnosed with colovesical fistula.

Case Report

A 11-year-old girl was referred to our center because of an increase in serum creatinine, colostomy dysfunction and abdominal pain. She was the last child of unrelated parents who came from Afghanistan. Her older siblings were

*Corresponding author: Arefeh Zahmatkesh, Email: arefeh.zhmtksh@gmail.com, arefeh.zhmtksh@sbmu.ac.ir

healthy and showed no abnormalities. She had a history of an imperforate anus, a single kidney, and recurrent UTIs. In addition, she was diagnosed with VACTERL due to multiple organ abnormalities and her karyotype analysis at another center revealed a female chromosome (XX) genotype (Figure 1).

In addition, the colostomy bag had been used for an extended period of time due to an unsuccessful operation to open the imperforate anus. It was noticeable that her UTI recurred and persisted on various antibiotics. During her examinations, we found sacral agenesis and vertebral abnormalities related to her history and fever. At our center we performed a VCUg (voiding cystourethrogram) which revealed a high grade (grade V) vesicoureteral reflux (VUR) in the left kidney. In addition, due to the fever and history of recurrent UTIs, and colostomy malfunctions, a barium enema was performed, which revealed a colovesical fistula (Figure 2).

Due to her poor kidney function and electrolyte imbalance, as well as intermittent volume overload, she was eventually diagnosed with end-stage renal disease (ESRD). Three-weekly hemodialysis was considered. She is also a candidate for surgical procedures for colovesical fistula fixation, genital reconstruction, and colostomy repair.

Discussion

Here we presented a rare case of colovesical fistula in a known diagnosed VACTERL syndrome with barium enema. Colovesical fistula is a rare malformation in children that is an abnormal connection between the bladder and the large intestine (9). Colovesical fistulas can be fatal from urosepsis (10), with an incidence rate of approximately 1 in 3000 patients hospitalized for surgery. The rate of all anorectal malformations is approximately 1 in 5000 live births and this colovesical fistula is an anorectal malformation (11). Therefore, early diagnosis and treatment of colovesical fistulas are essential.

Another essential manifestation in our patients was ambiguous genitalia. In a study of 105 patients with VACTERL syndrome, 56% of women had urogenital abnormalities, 33% had urogenital fistula, and 20% had structural abnormalities of the genitals such as micropenis (6). In addition, one of the most complex congenital anomalies of the pelvic organ in women, with an incidence rate of 1 in 50000 births, is cloacal malformation. Up to 10% of these patients present with syndromic abnormalities associated with chromosomal or genetic abnormalities (12).

In addition, due to the close development of the urogenital and renal systems from the hindgut, these malformations mostly occur together. Several studies have demonstrated that renal and urogenital anomalies are common (69-93%), particularly when anorectal malformations, urogenital defects or lower vertebral defects are present (13). These results are consistent with our case report. In our case study, there was a predisposition to

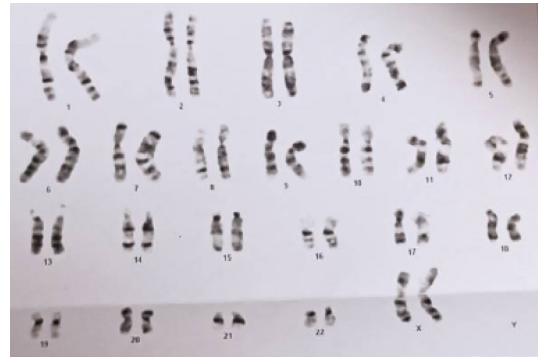

Figure 1. The karyotype analysis, the comparison of chromosome measurements, from peripheral blood samples showed chromosome XX. No Y chromosomes were recognizable.

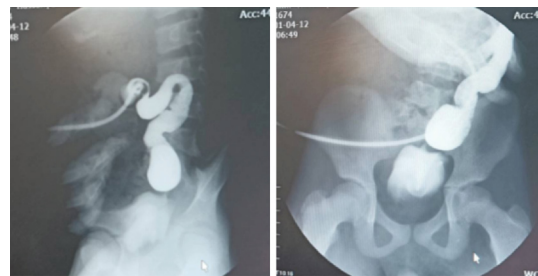


Figure 2. The barium enema result in a colovesical fistula.

recurrent UTIs. A study of 220 VACTERL patients showed that the most common renal manifestation in patients was VUR causing UTIs and renal scarring (14). However, the cause of recurrent UTIs in our patients was a colovesical fistula. We need to consider other comorbidities like VUR. A long-term follow-up of 12 VACTERL patients showed that the development of ESRD was more common in VACTERL patients compared to the placebo-matched group, and had more deficient dialysis and transplant outcomes (15).

Conclusion

In summary, abnormalities that could cause complications such as UTIs may go unnoticed. The study of relative anomalies should be conducted with extreme care. The diagnosis would be beneficial in deciding on the best treatment, particularly in symptomatic patients (such as fever and abdominal pain as characterized in our VACTERL case) and/or those suffering from organ failure.

Acknowledgments

We thank the patient and her family for their contribution to this study.

Authors' contribution

Conceptualization: Paniz Pourpashang, Seyed Mohammad Taghi Hosseini Tabatabaei.

Data curation: Paniz Pourpashang, Seyed Mohammad Taghi Hosseini Tabatabaei.

Formal analysis: Paniz Pourpashang.

Investigation: Paniz Pourpashang, Mina Vatanpour.

Methodology: Paniz Pourpashang, Mina Vatanpour, Arefeh Zahmatkesh.

Project administration: Arefeh Zahmatkesh.

Resources: Seyed Mohammad Taghi Hosseini Tabatabaei.

Supervision: Seyed Mohammad Taghi Hosseini Tabatabaei.

Validation: Seyed Mohammad Taghi Hosseini Tabatabaei, Paniz Pourpashang.

Visualization: Paniz Pourpashang, Seyed Mohammad Taghi Hosseini Tabatabaei.

Writing—original draft: Paniz Pourpashang, Arefeh Zahmatkesh.

Writing—review and editing: Arefeh Zahmatkesh.

Conflicts of interest

The authors declare that they have no competing interests.

Ethical issues

This case report was conducted in accord with the World Medical Association Declaration of Helsinki. Informed consent was obtained from the parents of the patient prior to their child's inclusion in the study. Ethical issues (including plagiarism, data fabrication, double publication) have been completely observed by the authors.

Funding/Support

The authors received no specific funding for this research.

References

- Hughes IA, Houk C, Ahmed SF, Lee PA; Lawson Wilkins Pediatric Endocrine Society/European Society for Paediatric Endocrinology Consensus Group. Consensus statement on management of intersex disorders. *J Pediatr Urol.* 2006;2:148-62. doi: 10.1016/j.jpuro.2006.03.004.
- Indyk JA. Disorders/differences of sex development (DSDs) for primary care: the approach to the infant with ambiguous genitalia. *Transl Pediatr.* 2017;6:323-34. doi: 10.21037/tp.2017.10.03
- Solomon BD. VACTERL/VATER Association. *Orphanet J Rare Dis.* 2011;6:56. doi: 10.1186/1750-1172-6-56.
- Raam MS, Pineda-Alvarez DE, Hadley DW, Solomon BD. Long-term outcomes of adults with features of VACTERL association. *Eur J Med Genet.* 2011;54:34-41. doi: 10.1016/j.ejmg.2010.09.007.
- Uehling DT, Gilbert E, Chesney R. Urologic implications of the VATER association. *J Urol.* 1983;129:352-4. doi: 10.1016/s0022-5347(17)52093-5.
- Solomon BD, Raam MS, Pineda-Alvarez DE. Analysis of genitourinary anomalies in patients with VACTERL (Vertebral anomalies, Anal atresia, Cardiac malformations, Tracheo-Esophageal fistula, Renal anomalies, Limb abnormalities) association. *Congenit Anom (Kyoto).* 2011;5:87-91. doi: 10.1111/j.1741-4520.2010.00303.x.
- Botto LD, Houry MJ, Mastroiacovo P, Castilla EE, Moore CA, Skjaerven R, et al. The spectrum of congenital anomalies of the VATER association: an international study. *Am J Med Genet.* 1997;71:8-15. doi: 10.1002/(sici)1096-8628(19970711)71:1<8::aid-ajmg2>3.0.co;2-v.
- Rittler M, Paz JE, Castilla EE. VACTERL association, epidemiologic definition and delineation. *Am J Med Genet.* 1996;63:529-36.
- Levitt MA, King SK, Bischoff A, Alam S, Gonzalez G, Pena A. The Gonzalez hernia revisited: use of the ischioanal fat pad to aid in the repair of rectovaginal and rectourethral fistulae. *J Pediatr Surg.* 2014;49:1308-10. doi: 10.1016/j.jpedsurg.2013.10.020.
- Smith CA, Avansino J. Anorectal Malformations. 2022 Aug 8. In: *StatPearls.* Treasure Island (FL): StatPearls Publishing; 2023.
- Pugh JI. On the pathology and behaviour of acquired non-traumatic vesico-intestinal fistula. *Br J Surg.* 1964;51:644-57. doi: 10.1002/bjs.1800510903.
- Wijers CH, van Rooij IA, Marcelis CL, Brunner HG, de Blaauw I, Roeleveld N. Genetic and nongenetic etiology of nonsyndromic anorectal malformations: a systematic review. *Birth Defects Res C Embryo Today.* 2014;102:382-400. doi: 10.1002/bdrc.21068.
- Solomon BD, Pineda-Alvarez DE, Raam MS, Bous SM, Keaton AA, Vélez JL, et al. Analysis of component findings in 79 patients diagnosed with VACTERL association. *Am J Med Genet A.* 2010;152A:2236-44. doi: 10.1002/ajmg.a.33572.
- Cunningham BK, Khromykh A, Martinez AF, Carney T, Hadley DW, Solomon BD. Analysis of renal anomalies in VACTERL association. *Birth Defects Res A Clin Mol Teratol.* 2014;100:801-5. doi: 10.1002/bdra.23302.
- Ahn SY, Mendoza S, Kaplan G, Reznik V. Chronic kidney disease in the VACTERL association: clinical course and outcome. *Pediatr Nephrol.* 2009;24:1047-53. doi: 10.1007/s00467-008-1101-x.

Copyright © 2023 The Author(s); Published by Nickan Research Institute. This is an open-access article distributed under the terms of the Creative Commons Attribution License (<http://creativecommons.org/licenses/by/4.0>), which permits unrestricted use, distribution, and reproduction in any medium, provided the original work is properly cited.