



A staggering recovery of an adolescent boy with crescentic glomerulonephritis despite numerous poor prognostic factors following early therapy

Behcet Simsek*^{ID}

Department of Pediatric Nephrology, Near East University School of Medicine, Nicosia, Cyprus

ARTICLE INFO

Article Type:
Case Report

Article History:

Received: 17 Jan. 2024

Accepted: 7 Apr. 2024

Published online: 25 May 2024

Keywords:

Crescentic glomerulonephritis treatment, Poststreptococcal glomerulonephritis, Plasmapheresis, Post-infectious glomerulonephritis, Rapidly progressive glomerulonephritis, Children

ABSTRACT

Poststreptococcal glomerulonephritis (PSGN) is a frequent, generally benign nephritis of childhood, yet, rarely shows a more aggressive rapidly progressive pattern as crescentic glomerulonephritis (CGN) histologically. It might end up in irreversible kidney failure, unless diagnosed and started a specific therapy shortly. However, due to the shortage of data for children, adult guidelines for CGN, have still made up the cornerstone of the therapy and management strategies in childhood. There are numerous parameters ending up with a poor outcome; alike elderly child age, male gender, initial severe acute kidney injury, nephrotic syndrome, hypertension and widespread crescents in 100% of glomeruli. This case presented here, reports a unique clinical and histological recovery story of a 13-year-old boy with poststreptococcal glomerulonephritis associated rapidly progressive glomerulonephritis (PSGN) following a promptly provided aggressive therapy, despite associated serious poor prognostic factors.

Implication for health policy/practice/research/medical education:

Our case report shows early diagnosis and immediate aggressive treatment of rapidly progressive glomerulonephritis in children with poststreptococcal glomerulonephritis are the best predictors of a favorable outcome.

Please cite this paper as: Simsek B. A staggering recovery of an adolescent boy with crescentic glomerulonephritis despite numerous poor prognostic factors following early therapy. J Renal Inj Prev. 2024; 13(3): e34302. doi: 10.34172/jrip.2024.34302.

Introduction

Occurring particularly in resource-limited countries, poststreptococcal glomerulonephritis (PSGN), has been the most common cause of acute nephritis in children globally, with an annual incidence of 9.5-28.5 per 100 000 individuals. The prognosis is generally favorable, amid not benign in some cases with a rapidly progressive glomerulonephritis (RPGN) (1,2).

Histologically, RPGN is characterized by a crescentic glomerulonephritis (CGN), representing cellular crescent formation due to severe glomerular injury (2). Histological classification covers three major groups: anti-glomerular basement membrane (GBM) nephritis (12%), immune complex nephritis (45%), pauci-immune disease associated with ANCA (42%) and less commonly other forms of proliferative glomerulonephritis (idiopathic/overlap disorders) (3).

Gross hematuria (50% to 85%), edema (13% to 80%), anemia (70%), and hypertension (63% to 85%) are among major clinical manifestations of CGN, amid nephrotic syndrome in association with a rapid onset kidney failure (3). Yet, as a clinical entity, RPGN is typically described as a rapidly developing nephritis with a sudden decline in renal function, associated with crescent formation in >50% of the glomeruli in a histologic specimen (2,4). Though, it has been claimed as the most frequent immunologic entity causing acute kidney injury in children; to date, only a few publications on the clinical course and treatment have been published (5-8). Moreover, it has been experienced that RPGN/CGN might end up in irreversible kidney failure within weeks, unless diagnosed and started a specific therapy promptly (2,9). However, due to the shortage of data for children, adult guidelines for CGN, have still made up the cornerstone of the therapy and

*Corresponding author: Behcet Simsek, Email: drmagoo.uk@gmail.com

management strategies in childhood (6,10).

The presence of additional parameters aside from early diagnosis and treatment, which have major impacts on the prognosis should be remembered during managing children with RPGN. Underlying type of CGN in association with the high percentage of crescentic glomeruli on renal biopsy brings an adverse effect on outcome, amid a favorable prognosis in that with a post-infectious origin. Moreover, male gender, initially observed nephrotic syndrome, acute kidney injury and subsequently provided dialysis treatment, arterial hypertension, disease relapse during follow-up, and being at an age older than twelve are emerging parameters which have been reported to be associated with an unfavorable prognosis (5). Despite associated numerous poor outcome parameters; such as elderly child age, male sex, initial severe acute kidney injury, nephrotic syndrome, hypertension and widespread crescents in 100% of glomeruli, this case, reports a unique clinical and histological recovery story of a 13-year-old boy with PSGN associated RPGN following a promptly provided aggressive therapy.

Case Presentation

A 13-year-old boy who had previously been well with no ever such complains as hemoptysis, joint tenderness or skin rash, but suffered from acute pharyngitis about 10 days ago, was consulted to our unit with a 2-day history of painless coke colored macroscopic hematuria, headache, decreased urine output and edema particularly in the eye lids and legs. There was no family history of renal disease.

Clinical findings

His body temperature was 36.9 °C heart rate: 108/min, blood pressure (BP): 155/100 mm Hg (systolic >95th centile, diastolic >95th centile), Breath rate was 22/min on admission. Pharynx was hyperemic, lung sounds were coarse, in particular with rales in both basales. He had anasarca with +2 pitting edema in lower extremities. X-ray of lungs revealed interstitial edema with fluid in both sinuses.

Diagnostic assessment and follow up in the ward

Following transferred to the ward, the boy had oliguria <1 mL/kg/h with continuing macroscopic urine. Initial laboratory findings were as follows: hemoglobin – 10.1 g/dL, white blood cell count – $12.4 \times 10^3/\mu\text{L}$, platelets – $359 \times 10^3/\mu\text{L}$, serum electrolyte levels – within normal range, serum total protein – 5.5 g/dL, serum albumin – 2.3 g/dL, total cholesterol – 204 mg/dL, triglyceride – 196 mg/dL, creatinine – 1.8 mg/dL, BUN – 44 mg/dL. Additionally, the infectious screen was negative for both hepatitis viruses and syphilis. Proteinuria (++++) was also observed in urine analysis. The autoimmune screen revealed normal level of complement protein 4, but low complement protein 3 (71 mg/dL), negative anti-nuclear antibodies (ANA) and anti-dsDNA, negative anti-neutrophil cytoplasmic antibodies (p and cANCA). Anti-streptolysin titer (ASO) was 275 units/mL. Urinary ultrasound examination showed increased-sized kidneys (vertical length: 125.4 mm (>97.5p)) with increased echogenicity and faded cortico-medullary differentiation (11). Chest X-ray showed interstitial infiltration with edema and minor pleural effusion in both sinuses. Initially, post-infectious, particularly post-streptococcal glomerulonephritis was considered as a diagnosis, a benzathine penicillin shot was provided and conservative treatment was initiated accordingly. In the following 24 hours, the boys' clinical wellbeing worsened with coughing and shortness of breath, tachycardia and headache, BP – 150/90 mm Hg, anasarca and oliguria <0.5 mL/kg/24 h. Laboratory tests revealed a decline in serum albumin to 2.0 g/dL, soaring in serum creatinine to 4.7 mg/dL, which was up from 1.8 mg/dL, urinary protein – 6.1 g/d (177 mg/m²/h). This progressive entity was considered primarily as RPGN. Kidney biopsy was performed promptly. Thereafter, aggressive plasmapheresis on alternate days at six total doses were started associated with induction therapy with pulse methylprednisolone, prednisone and cyclophosphamide according to the protocol revealed by Bagga (Table 1) (12). Dramatic clinical recovery of symptoms was achieved with the treatment within 2 weeks.

Table 1. Treatment of crescentic glomerulonephritis (adapted from Bagga (12))

Induction phase (3-6 months)	Maintenance phase (2-5 years)
Methylprednisolone 15-20mg/kg (maximum 1g) IV Daily for 3-6 doses	
Prednisone 1.5-2 mg/kg/d PO for 4 weeks; taper to 0.5 mg/kg Daily by 3 months; 0.5-1 mg/kg on alternate day for 3 months	Prednisone 0.5-1 mg/kg on alternate days; later taper
Cyclophosphamide 500-750 mg/m ² IV every 3-4 weeks for 6 pulses ^a	Consider mycophenolate mofetil (1000-1200 mg/m ² /day), if disease activity is not controlled
Plasmapheresis (double volume) on alternate days for 2-weeks ^b	
Agents for refractory disease	
Intravenous immunoglobulin, TNF-α antibody (infliximab), anti CD20 (rituximab)	

^a The dose of cyclophosphamide is increased to 750 mg/m² if no leukopenia. Dose reduction is necessary in patients showing impaired renal function. Alternatively, the medication is given orally at a dose of 2 mg/kg daily for 12 weeks.

^b Plasmapheresis should begin early, especially if patient is dialysis dependent at presentation or if biopsy shows severe histological changes (>50% crescents). Plasma exchange is particularly useful in anti-GBM nephritis and ANCA-associated vasculitis. It might be considered in patients with immune complex GN with unsatisfactory renal recovery after steroid pulses.

Urine output increased to normal range, BP normalized, pleural effusion resolved. Serum albumin level increased to 3.6 g/dL, amid continuing proteinuria at 2.5 g/d. Serum creatinine decreased to 0.89 mg/dL. Then the patient was discharged to continue the treatment as outpatient.

Outpatient follow up and outcome

After 4 weeks from the start of the symptoms, the patient admitted with respiratory infection, loss of appetite, fatigue, edema, hypertension with 140/90 mm Hg, serum albumin – 2.9 g/dL, creatinine 1.7 mg/dL, ESR: 33 mm/h and proteinuria – 4.1 g/d. A second kidney biopsy was performed to investigate the situation. No complication was encountered in neither of the biopsy procedure. The ongoing treatment protocol was continued following 3 additional pulse methylprednisolone infusion. The first biopsy revealed cellular crescents in 100% of the 24 glomeruli on the slide, with endocapillary cellular activity with polymorphonuclear leukocyte infiltration in addition to strong C3 staining, pointing out diffuse proliferative crescentic GN associated with acute crescentic post-infectious GN (Figure 1).

The latter biopsy showed normal glomeruli in >50% of 17 glomeruli in the specimen and global sclerosis in one glomerulus and fibro-cellular crescents in the remaining 7 glomeruli besides weak C3 staining. These findings were considered to be associated with the late stage of a post-infectious crescentic GN. Thickening in glomerular basal membrane and lamina densa, increased mesangial matrix, electron dense deposit in particular along glomerular basal membrane lamina densa and mesangium, diffuse obliteration in the foot processes of podocytes and capillary endothelial edema and obliteration were observed in electron microscopic examination (Figure 2).

During the latter follow-up, the boy has recovered steadily and subsequently become free of all the signs and symptoms after 18 months. After 1 month from

the initiation of treatment C3 level became normal (149 mg/dL (N: 80-170 mg/dL)) and serum albumin – 3.6 g/dL, serum creatinine – 0.73 mg/dL, however even after 6 months urine protein was still 2.43 g/d with (+++) proteinuria, amid serum albumin – 4.5 g/dL. Hardly after 18 months, urine analysis became free of protein [urine protein: (-)] with urine microalbumin of 13.8 mg/dL. Serum creatinine was 0.79 mg/dL and albumin – 4.5 g/dL at that time. The treatment protocol was tapered in 3 years with mycophenolate mofetil (MMF) and then quitted, providing a 3 years' period, free from any treatment by the time this report is being written. Currently, after 6 years from the beginning of treatment start, the patient is still free of symptoms with normal BP and no proteinuria, normal serum albumin levels (4.5 g/dL) and serum creatinine (0.82 mg/dL) with eGFR >100 mL/min/1.73 m².

Discussion

Duration of disease, which defines the period from first clinical signs to diagnosis and therapy have been revealed to be among parameters, critically affecting the course and outcome of CGN (6,9). El-Husseini et al, advocated the time of therapy initiation to be the best predictor of the outcome for CGN (13). Dewan et al reported that the mean duration of symptoms before diagnosis in their study population of 22 children were 2.47 months, and the majority of patients had already been dialysis dependent from presentation onwards; amid normal serum creatinine levels at last visit in merely 35% (8). In the series of Özlü et al, consisting of 45 biopsy-proven CGN cases, mean duration before diagnosis was revealed to be 26±12 days, and subsequently 19/45 (42%) patients developed chronic kidney disease (7). Such an adverse outcome was commented to be significantly associated with a long duration between the onset of symptoms and treatment (7,8). In our patient, kidney biopsy was performed on the 4th day from the very early symptoms

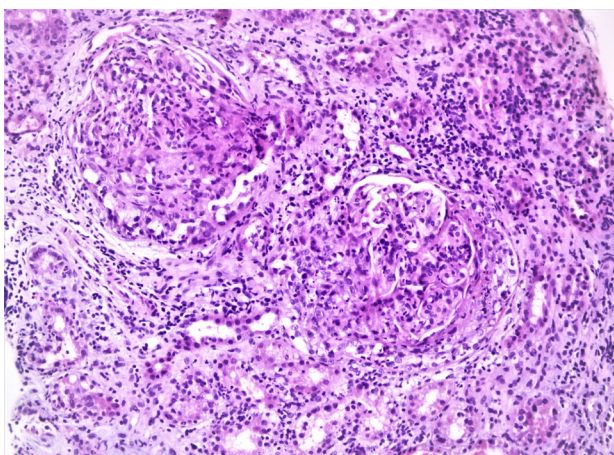


Figure 1. Diffuse proliferation in glomeruli with the presence of polymorphonuclear leukocyte (PMNL) and crescent formation (H&E ×200).

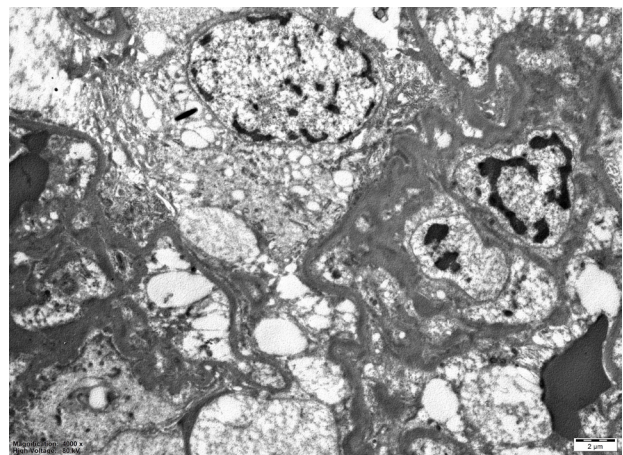


Figure 2. Electron dense areas along lamina densa and mesangium along with obliteration in foot process and capillary lumen with endothelial edema.

of the disease, enabling a quite early diagnosis, comparing with the previously mentioned series. Thereafter, an aggressive treatment was initiated promptly. Considering the total clinical recovery and a favorable outcome with early diagnosis and emergent therapy in our patient, this report supports El-Husseini's comments, underscoring the high significance of early start of therapy over the outcome and consequences of CGN (13).

There might be numerous factors on renal biopsy examination, affecting the course of CGN. A successful treatment might desperately be dependent on underlying diseases of CGN and the severity of histopathological findings, i.e. the percentage of glomeruli with crescents, amount of tubular atrophy/interstitial fibrosis and necrosis on pathological samples (6). It was previously revealed that the severity of disease is associated with the degree of crescent formation and those with crescents in over 80% of glomeruli are prone to present advance kidney failure despite therapy (2,13). In the prior kidney biopsy samples of the boy being presented herein, cellular crescents were observed in 100% of the glomeruli. Following prompt and aggressive therapy, a total recovery from crescents in over 50% of the affected glomeruli, were confirmed by a subsequent biopsy. After a 6-year follow up, serum creatinine of the patient is 0.71 mg/dL and eGFR=100.05 mL/min/1.73 m² according to bedside Schwartz equation, clearly contradicting with the common experience (7). Despite the general consensus regarding the fact that higher percentage of crescentic glomeruli breeds kidney failure, presence of cellular crescents, rather than fibrous crescents and chronicity indices observed in biopsy which are predictors of poor renal survival, might be associated with the favorable outcome in our patient (2,4,6,9,13).

Underlying disease has also a critical impact over treatment success and course of CGN, in addition to early diagnosis, aggressive therapy, and the percentage of crescentic glomeruli on renal biopsy (6,9). RPGN secondary to post-infectious glomerulonephritis (PIGN) has a good prognosis, amid those of immune-complex mediated or lupus nephritis with high ratios of end stage kidney disease at over 50% and 30% respectively (9). The boy who has been presented here had suffered from RPGN secondary to PIGN which might have brought such a favorable outcome.

Cases with severe acute kidney injury at the time of diagnosis initially requiring dialysis and occasions with fast developing or fulminant course of disease showed minor improvement in renal function and resulted in a higher percentage of end-stage renal disease. Additionally, children with disease relapse during follow-up, who are elderly over 12 years, in particularly male gender, those with arterial hypertension or nephrotic syndrome at presentation, had a worse outcome (6,10). Despite having nephrotic syndrome, a fulminant disease duration and arterial hypertension, our adolescent boy has managed to survive a good prognosis, which might underline the

superior impact of prompt treatment initiation over other adversely affecting parameters regarding the outcome.

Interestingly, Mayer et al, revealed high kidney volume to be a good non-invasive parameter for the diagnosis of CGN (6). The ultrasound (USG) examination of the kidneys of our case has supported this finding, indeed. Thus, we claim that USG examination should be an important and prompt tool in the approach of not only CGN but also numerous glomerulopathies as well.

Immune-complex glomerulonephritis has been the leading cause of CGN, including IgA nephropathy, Henoch-Schönlein nephritis in children, amid pauci-immune CGN in adults (6,7). However, PSGN was stated to be more common in developing countries, being consistent with the diagnosis of our patient (8).

Despite rarely seen extensive crescents and unclear benefits of intensive immunosuppressive therapy in PSGN, immunosuppressive therapy has been provided in those with renal failure and widespread glomerular crescents (12). Urgent aggressive therapy is pivotal for a favorable renal outcome (6,8,9). However, specific treatment guidelines for crescentic RPGN in children are mostly based on adult experiences due to limited pediatric data. High dose methyl prednisolone and cyclophosphamide pulses have still been the initial therapy followed by low dose prednisolone and mycophenolate mofetil as maintenance therapy in diverse centers likewise our unit (6,9,12). Experiences with multiple agents like, rituximab and TNF- α receptor blocker (etanercept) have shown promising results in adults and children as well (9).

Plasmapheresis has also been in use with diverse success in CGN cases. Rapidly removing the antibodies in disease development, it might avert end-organ damage. Therapeutic plasmapheresis is not only recommended for patients with pauci-immune crescentic GN, anti-GBM GN but also for those with refractory immune-complex RPGN (9). Urgent plasmapheresis administration in this case is being considered to contribute to treatment success and the favorable outcome.

In the boy presented here, Bagga's protocol was followed with plasmapheresis. Prominent treatment success was achieved with early start of this therapy, followed by a good prognosis, confirmed by highly conserved renal function after 6 years and pathological proof (12).

Fulminant course of disease with initial dialysis, disease relapse during observation, male gender, arterial hypertension or nephrotic syndrome at presentation, and age >12 years are yet among worse prognostic factors in various types of CGN. However, prompt diagnosis and therapy initiation might be the sole emerging best predictors of prognosis in RPGN secondary to PSGN (2,6-9,13).

Conclusion

This case experience underscores that, early diagnosis and immediate aggressive treatment of RPGN in children

with PSGN are the best predictors of a favorable outcome. Additionally, PSGN might still be a vital type of CGN, clinicians could come across. Finally, multicenter collaborations and data sharing with clinical registries in this relatively rare, but desperate emergency, have pivotal roles to improve our understanding and skills to refine therapeutic protocols for children.

Acknowledgements

I do appreciate Prof. Dr. Seyhun Solakoğlu and co-workers in İstanbul University School of Medicine Department of Histology and Embryology; İstanbul, and Assoc. Prof. Dr. Gülistan Gümrükçü and co-workers in Republic of Türkiye Health Ministry Health Sciences University Haydarpaşa Numune Research and Training Hospital Department of Pathology, examining the biopsy materials in our patient.

Conflicts of interest

The author declares that there is no competing interest.

Ethical issues

This case report was conducted in accord with the World Medical Association Declaration of Helsinki. The legal guardian of the patient has provided written informed consent for the publication of a case report. Ethical issues (including plagiarism, data fabrication, double publication) have been completely observed by the author.

Funding/Support

No funding or support was achieved for this case report.

References

1. Carapetis JR, Steer AC, Mulholland EK, Weber M. The global burden of group A streptococcal diseases. *Lancet Infect Dis.* 2005;5:685-94. doi:10.1016/S1473-3099(05)70267-X.
2. Greenhall GH, Salama AD. What is new in the management of rapidly progressive glomerulonephritis? *Clin Kidney J.* 2015;8:143-50. doi: 10.1093/ckj/sfv008.
3. Eddy AA. Glomerular Diseases. In: Rudolph CD, Rudolph AM, Lister GE, Lewis RF, Gershon AA, eds. *Rudolph's Pediatrics.* 22nd ed. McGraw Hill; 2023. p. 16-18.
4. Jennette JC. Rapidly progressive crescentic glomerulonephritis. *Kidney Int.* 2003;63:1164-77. doi: 10.1046/j.1523-1755.2003.00843.x.
5. Jardim HM, Leake J, Risdon RA, Barratt TM, Dillon MJ. Crescentic glomerulonephritis in children. *Pediatr Nephrol.* 1992;6:231-5. doi: 10.1007/BF00878354.
6. Mayer U, Schmitz J, Bräsen JH, Pape L. Crescentic glomerulonephritis in children. *Pediatr Nephrol.* 2020;35:829-842. doi: 10.1007/s00467-019-04436-y.
7. Özlü SG, Çaltık A, Aydoğ Ö, Bülbül M, Demircin G, Çakıcı E, et al. Crescentic glomerulonephritis in children: a single centre experience. *World J Pediatr.* 2016;12:225-30. doi: 10.1007/s12519-015-0036-0.
8. Dewan D, Gulati S, Sharma RK, Prasad N, Jain M, Gupta A, et al. Clinical spectrum and outcome of crescentic glomerulonephritis in children in developing countries. *Pediatr Nephrol.* 2008;23:389-94. doi: 10.1007/s00467-007-0647-3.
9. Moorani KN, Aziz M, Amanullah F. Rapidly progressive glomerulonephritis in children. *Pak J Med Sci.* 2022;38:417-425. doi: 10.12669/pjms.38.ICON-2022.5774.
10. Moroni G, Ponticelli C. Rapidly progressive crescentic glomerulonephritis: Early treatment is a must. *Autoimmun Rev.* 2014;13:723-9. doi: 10.1016/j.autrev.2014.02.007.
11. Kecler-Pietrzyk A, Knipe H, Gündüzöz A, et al. Normal kidney size (children). *Radiopaedia.org.* doi:10.53347/rID-53062.
12. Bagga A. Crescentic glomerulonephritis. In: Avner ED, Harmon WE, Niaudet P, Yoshikawa N, eds. *Pediatric Nephrology.* 6th ed. Springer; 200. p. 839-53.
13. El-Husseini AA, Sheashaa HA, Sabry AA, Moustafa FE, Sobh MA. Acute postinfectious crescentic glomerulonephritis: clinicopathologic presentation and risk factors. *Int Urol Nephrol.* 2005;37:603-9. doi: 10.1007/s11255-005-0399-6.

Copyright © 2024 The Author(s); Published by Nickan Research Institute. This is an open-access article distributed under the terms of the Creative Commons Attribution License (<http://creativecommons.org/licenses/by/4.0>), which permits unrestricted use, distribution, and reproduction in any medium, provided the original work is properly cited.